

# Minimally invasive calcaneal fixation for displaced intra-articular fractures

**Maire-Clare Killen** and **Rajiv Limaye** describe the technique and report outcomes of a series of patients undergoing minimally invasive fixation for displaced intra-articular fractures using the Wave plating system

The calcaneus is the most commonly fractured tarsal bone, with intra-articular fractures accounting for up to 75 per cent of all calcaneal injuries; these fractures in particular are associated with a high rate of morbidity and overall poor outcome [1–4].

There are numerous classification systems used to describe fractures of the calcaneus, with Sanders' classification being one of the most commonly utilised [5]. This system is based on the number of articular fragments on a Coronal CT scan. Type I fractures are un-displaced; type II involve two articular fragments; type III involve three articular fragments; and type IV fractures have more than three articular fragments. These can be further sub-divided into types A, B and C depending on the location of the fracture lines in the posterior facet (Figure 1).

Treatment of calcaneal fractures as a whole remains controversial, with no clear consensus on whether operative fixation is superior to conservative management alone. There is some evidence to suggest that displaced intra-articular fractures have improved outcomes if they undergo anatomic reduction and fixation in order to restore the calcaneal shape and subtalar joint, leading to better functional scores and lower rates of secondary subtalar arthritis [6].

Fractures deemed significant enough to warrant surgical intervention were traditionally treated with fixation via an open, extensile approach to the calcaneus. Although such an approach provides good exposure, allowing visualisation of the subtalar joint and ensuring adequate reduction, soft tissue complications and wound breakdown can be problematic.

More recently, minimally invasive techniques for fixation of such fractures have been increasingly described; by reducing the overall trauma to the surrounding soft tissues, a less-invasive approach aims to lower the risk of overall post-operative wound complications.

In this article, we describe the technique and report outcomes of a series of patients undergoing minimally invasive fixation for displaced intra-articular fractures using the Wave plating system.

## Surgical technique and case series

Patients were selected for operative management in cases of significantly displaced intra-articular fractures. Heavy smokers, patients with significant other co-morbidities, neurovascular compromise or poor soft tissue quality were excluded and managed non-operatively in a below-knee plaster.

The Wave plate (Tournier Inc, USA) was used in all cases; this system is specifically designed for use with a minimally invasive soft tissue approach.

## Surgical technique

Patients were operated on under a combination of general anaesthesia and high ankle block, using a tourniquet, with antibiotic prophylaxis at induction.

A small (approximately 5cm) incision was used overlying the subtalar joint to provide visualisation of the posterior facet and anterior process of the calcaneus. This incision avoids exposure and possible injury to the peroneal tendons and sural nerve. Soft tissue dissection was performed over the lateral border of the calcaneus using a periosteal elevator.

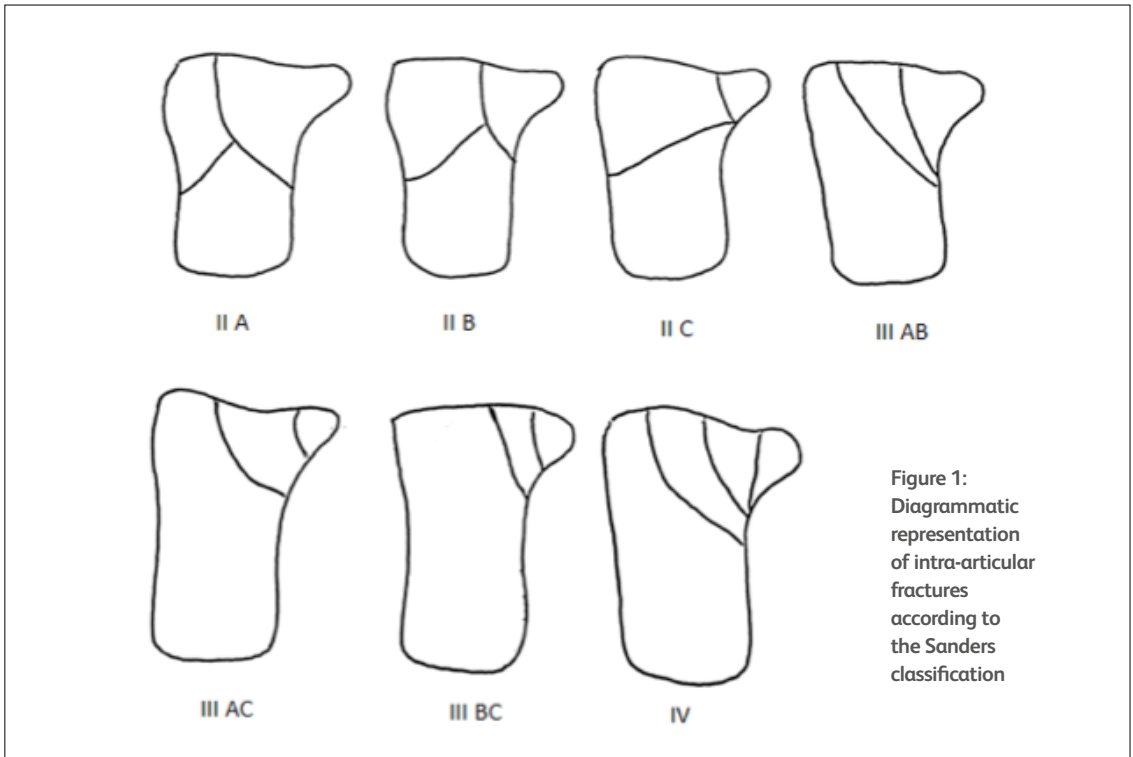
Following exposure, a laminar spreader was inserted into the subtalar joint to aid visualisation. A Schanz screw was inserted by hand into the posterior tubercle of the calcaneus and subsequently used as an aid to reduction.

Traction was applied to the forefoot, with counter-traction applied using the previously inserted Schanz screw. While applying traction, the heel was moved into varus to reduce the impacted fragments and then into valgus, using thumb pressure over the lateral wall for compression.

Temporary fixation was performed with guide pins and an appropriate sized plate was selected.

Using the drill guide as a handle, the posterior end of the plate was inserted through the incision and slid under the peroneal tendons onto the posterior tuberosity and along the exposed path.

The drill guide was then removed and the anterior end of the



**Figure 1:**  
Diagrammatic  
representation  
of intra-articular  
fractures  
according to  
the Sanders  
classification

plate inserted along the exposed path anteriorly, ensuring that all fracture fragments were lying medial to the plate.

Direct palpation and image intensifier was used to confirm adequate plate position.

A guide wire was inserted into the apex hole of the plate in the direction of the sustentaculum tali; the cannulated drill is used over this wire and a non-locking lag screw inserted.

Anterior locking screws were then inserted under direct vision. Following this, the two posterior holes in the plate were palpated and a small incision between them, parallel to the peroneal tendon, was used to insert the final screws.

Final AP, lateral and calcaneal view intra-operative radiographs were taken to confirm adequate reduction and fixation. The wound was closed with non-absorbable sutures and patients were put into a below-knee back-slab. Patients were mobilised non-weight bearing and discharged when they were safe to do so independently.

#### Follow up and review

All patients were followed up at two weeks for removal of sutures and change of backslab into a below-knee, lightweight, non-weight-bearing plaster for a further two weeks. At four weeks post-operatively, patients were placed into an air-cast boot and advised to remain non-weight bearing but to perform active range of motion exercises at the ankle joint.

Patients were reviewed at six weeks with further radiographs;

## Treatment of calcaneal fractures as a whole remains controversial, with no clear consensus on whether operative fixation is superior to conservative management alone.

full weight bearing and formal physiotherapy commenced at this stage.

In total, five patients were operated on using the minimally invasive technique and Wave plate as described above. The age of our patient cohort ranged from 16 to 49; there were three males and two females.

At present, follow-up of this patient group ranges from six to 17 months.

All patients had displaced intra-articular fractures of the calcaneus and this was the isolated injury in all cases.

Patients were operated on between six and 13 days after the initial injury, with the decision regarding operative timing being made on the basis of soft tissue swelling and tension.

Operative tourniquet time ranged from 49 to 78 minutes.

After the early follow up as described above, patients were reviewed again at three, six, nine and 12 months for further

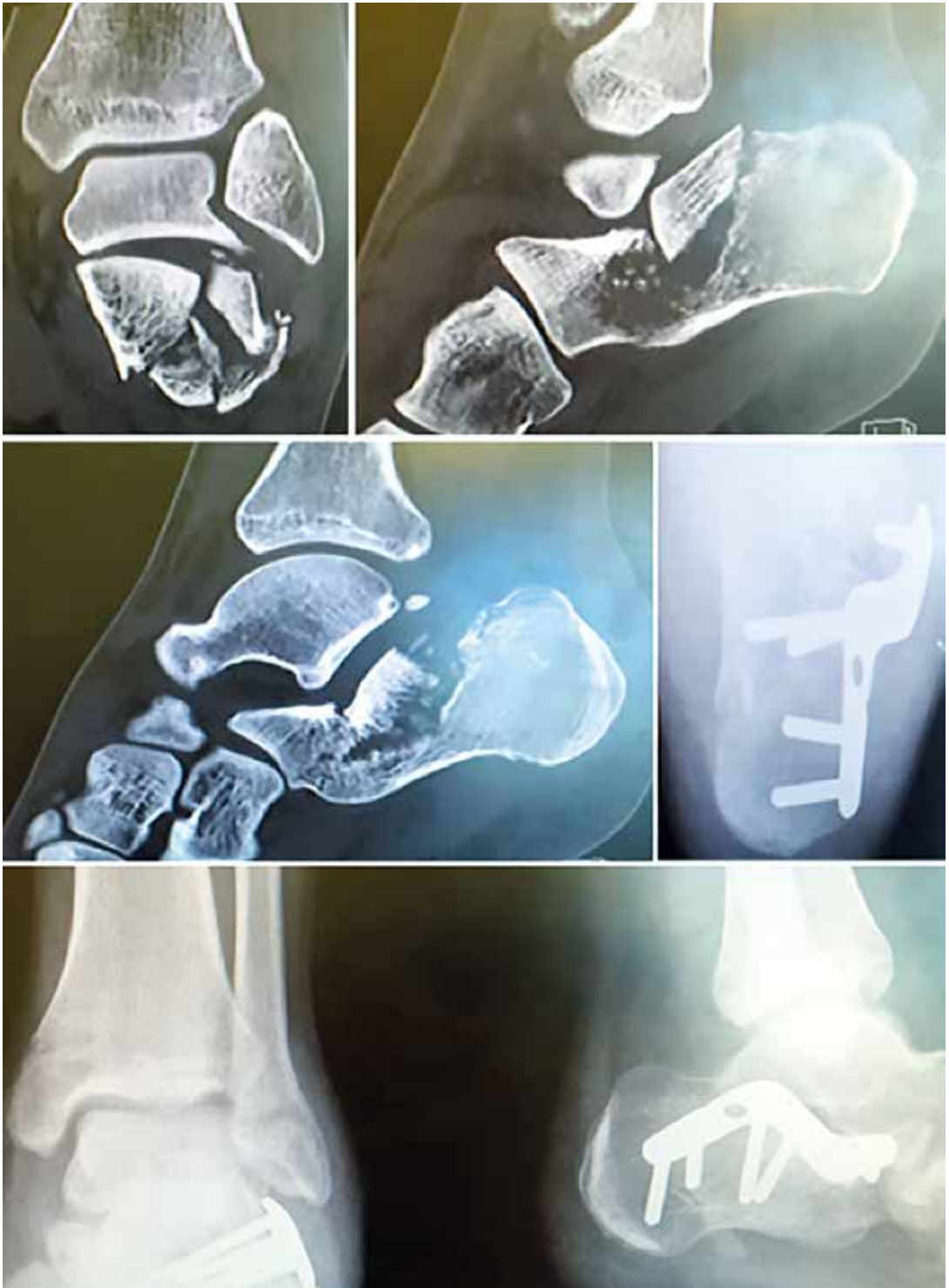

Figure 2: Pre-operative CT scan of a 28-year-old patient with a displaced intra-articular fracture and post-operative radiographs following operative fixation using the Wave plate.

assessment and completion of AOFAS scores.

The mean pre-operative AOFAS score was 20.8 (range 16–24) and this increased to 76.8 at 6 months post-operatively (range 70–85).

There were no patients in our group with any post-operative wound infections or skin breakdown. To date, there have been no problems with metalwork and there is no evidence of the development of subtalar osteoarthritis on most recent radiographs (Figure 2).

## Discussion

Calcaneal fractures are relatively common and can prove very difficult to treat, with high levels of long-term complications documented with both non-operative and operative management.

At present, there is no consensus on the best course of treatment for this group of patients. Some surgeons advocate surgical fixation for significantly displaced intra-articular fractures. The principles of operative fixation are to restore the subtalar joint, reducing the risk of secondary arthrosis as well as re-establishing calcaneal height, length and heel width to avoid problems with footwear. Surgical fixation however is not without risk; traditional expansile approaches to the calcaneus have been associated with high rates of soft tissue complications [7].

Incidence of skin necrosis following calcaneal fixation have been reported to vary between 2 and 11 per cent, with soft tissue infections ranging from 1.3 to 7 per cent following an extended open approach. Overall wound problems following such open approaches have been quoted to occur in up to 25 per cent of cases [8–12].

Concerns regarding wound healing complications following an extensile lateral approach have led to the development of alternative methods for the management of these fractures in order to minimise soft tissue trauma [13]. Minimally invasive fixation of calcaneal fractures is becoming an increasingly described and used technique, with evidence to support its advantages over the more traditional open approach, particularly in terms of lower rates of soft tissue complications.

Although a small series, we had no cases of post-operative wound complications and a significant increase in functional scoring post-operatively using a minimally invasive approach for displaced intra-articular fractures.

A 2013 comparative study of intra-articular fractures undergoing surgical fixation via either an extensile approach or minimally invasive sinus tarsi approach found the clinical outcomes to be similar; however, the minimally invasive approach had a significantly lower incidence of wound complications and need for second surgeries; 29 per cent of patients in the extensile approach group developed wound healing complications compared with 6 per cent in the minimally invasive group ( $P=0.005$ ) [13].

A 2014 systematic review has also demonstrated promising data, with the overall complication rate for percutaneous or minimally invasive procedures being much lower than for open techniques. However, they identified the need for further research, particularly randomised controlled trials to be able to guide definitive indications [14].

## Conclusion

There is increasing evidence to support minimally invasive fixation for displaced intra-articular fractures of the calcaneus. Our technique has demonstrated positive early outcomes in a small cohort of patients, with patient selection playing an important role in overall outcomes.

Further, higher-level evidence will be needed to give definitive indications and contra-indications to surgical intervention for such injuries.

## References

1. Daftary, A., Haims, A.H. & Baumgaertner, M.R. (2005) Fractures of the calcaneus: a review with emphasis on CT. *Radiographics* 25, 1215–1226
2. Koval, K.J. & Zuckerman, J.D. (2002) *Handbook of Fractures* (edition 2), Lippincott Williams & Wilkins
3. Juliano, P. & Nguyen, H.V. (2001) Fractures of the calcaneus. *Orthop. Clin. North Am.* 32, 35–51
4. McBride, D.J., Ramamurthy, C. & Laing, P. (2005) The hind foot: calcaneal and talar fractures and dislocation – part 1: fractures of the calcaneum. *Curr. Orthop.* 19, 94–100
5. Sanders, R., Fortin, P., DiPasquale, T. & Walling, A. (1993) Operative treatment in 120 displaced intra-articular calcaneal fractures: results using a prognostic computed tomography scan classification. *Clin. Orthop. Relat. Res.* 290, 87–95
6. Rammelt, S. & Zwipp, H. (2004) Calcaneus fractures: facts, controversies and recent developments. *Injury* 35, 443–461
7. Guerado, E., Bertrand, M.L. & Cano, J.R. (2012) Management of calcaneal fractures: What have we learnt over the years? *Injury* 43, 1640–1650
8. Bezes, H., Massart, P., Delvaux, D., et al. (1993) The operative treatment of intra-articular calcaneal fractures: indications, technique and results in 257 cases. *Clin. Orthop. Rel. Res.* 290, 55–59
9. Zwipp, H., Tscherne, H., Thermann, H. & Weber, T. (1993) Osteosynthesis of displaced intra-articular fractures of the calcaneus: results in 123 cases. *Clin. Orthop. Rel. Res.* 290, 76–86
10. Abidi, N.A., Dhawan, S., Gruen, G.S., et al. (1998) Wound-healing risk factors after open reduction and internal fixation of calcaneal fractures. *Foot Ankle Int.* 19, 856–861
11. Harvey, E.J., Grujic, L. & Early, J.S. (2001) Morbidity associated with ORIF of intra-articular calcaneus fractures using a lateral approach. *Foot Ankle Int.* 22, 868–873
12. Folk, J.W., Starr, A.J. & Early, J.S. (1999) Early wound complications of operative treatment of calcaneus fractures: analysis of 190 fractures. *J. Orthop. Trauma* 12, 369–372
13. Kline, A.J., Anderson, R.B. & Davis, W.H. (2013) Minimally invasive technique versus an extensile lateral approach for intra-articular calcaneal fractures. *Foot Ankle Int.* 34, 773–780
14. Wallin, K.J., Cozzetto, D., Russell, L., et al. (2014) Evidence-based rationale for percutaneous fixation technique of displaced intra-articular calcaneal fractures: A systematic review of clinical outcomes. *J. Foot Ankle Surg.* 53, 740–743